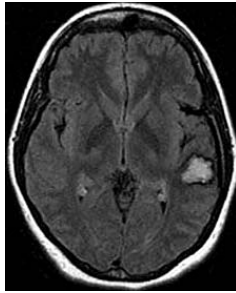
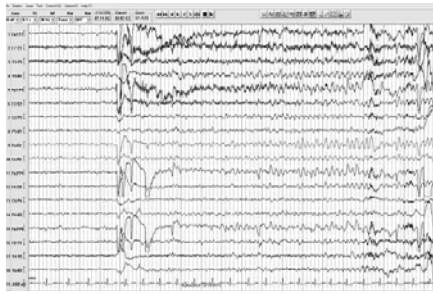


Epilepsy Case Study:

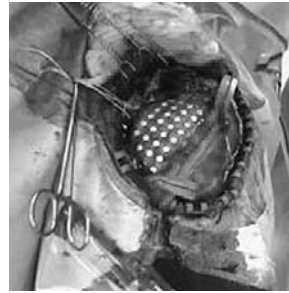32-year-old woman with chronic refractory epilepsy and left posterior temporal cavernous angioma.



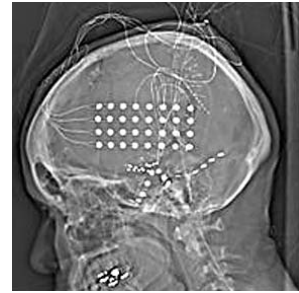
▲ Pre-operative Axial FLAIR MRI of Brain



▲ EEG Ictal Onset



▲ Cortical Grid Placement



▲ Post-implantation CT of Head

PATIENT HISTORY:

The patient is a 32-year-old woman who has had seizures since age 15. Her seizures were complex partial seizures with occasional secondary generalization. During a typical event she would demonstrate behavior arrest, blank stares and automatisms in both hands. This would last 30 - 90 seconds followed by post-ictal confusion. The patient has no history of auras. Over the years she has tried multiple anti-epileptic drugs (AEDs), but has never been able to totally control her seizures. She was found to have a vascular malformation in the left posterior superior temporal region on MRI of brain.

DISCUSSION:

Neuropsychologic testing showed a Verbal IQ of 84, Performance IQ of 99 and Full Scale IQ of 90. She had non-invasive video-EEG monitoring at the Epilepsy Monitoring Unit where two clinical seizures were captured. Both seizures had subtle left posterior temporal theta slowing, which quickly spread to the rest of the left and right hemisphere.

Clinically, one event had right automatisms first, though both events had more prominent automatisms on the left. The patient always looked to the left then later to the right.

She had ictal aphasia and an interictal EEG demonstrated independent bilateral fronto-temporal epileptiform discharges, more frequent on the left.

After discussing her case during an epilepsy conference, a functional MRI was obtained that demonstrated language dominance to the right hemisphere. An Intra-carotid Sodium Amytal (WADA) test was then performed. A superselective injection into the left posterior middle cerebral artery produced left hemispheric EEG slowing, but the patient maintained adequate auditory comprehension and language output. She showed mild difficulty with the repetition and moderate difficulties with naming. With left internal carotid artery (ICA) injection, the patient demonstrated clear impairment with language function. With the right ICA injection, the patient had mild dysarthria, but the language function was grossly intact. The memory function was localized more to the right hemisphere.

TREATMENT:

Due to concern that the patient's language function was clearly localized in the left hemisphere, and the fact that she has bilateral left more than right intermittent independent fronto-temporal epileptiform discharges,

over...

invasive monitoring was carried out to map her language cortex and further localize her seizures. A left craniotomy was performed and a cortical subdural grid was placed in the posterior frontal and lateral temporal cortex to cover the area overlying the cavernous angioma. Depth electrodes with the distal tip pointing toward the left mesial temporal structures (amygdala and hippocampus) were implanted. Subdural strips were placed via burr hole under the right basal temporal area with the distal end pointing toward the mesial temporal structures.

The patient then had continuous video-EEG monitoring. Functional mapping of the language area was performed at the bedside with an Ojemann Cortical Stimulator. It was localized to the anterior superior region approximately one centimeter from the cavernous angioma. The tissue surrounding the cavernous angioma was deemed an epileptogenic zone due to frequent epileptiform discharges. However, the epileptogenic focus was localized at the anterior superior corner of the cavernous angioma, in close proximity to the language cortex. Intermittent epileptiform discharges were captured from the distal end of the depth electrodes on the left and the basal strips under the right temporal region. Subclinical seizures were also captured from the left mesial temporal structures. It is likely the patient has dual pathology with one main seizure focus near the cavernous malformation at the lateral temporal cortex, but also another less active seizure focus in the mesial temporal area.

After carefully reviewing the available data with the neurosurgeon who performs epilepsy surgery, an awake

craniotomy was carried out. Functional mapping of the language cortex was again completed before the resection of the epileptogenic focus and the cavernous angioma. Electrocorticography was also utilized to guide the extent of the resection. The mesial temporal structure was left untouched with the hope that once the major seizure focus was removed, her current anti-epileptic medications would be adequate in controlling her seizures. It was also a concern that operating on both lateral cortex and mesial structures may increase the risk of creating post-operative deficits.

OUTCOME AND FOLLOW UP:

Post-operatively, the patient experienced transient difficulty with naming objects, but the difficulty was resolved within a few days with speech therapy. At the time of discharge, the patient did not have any significant language difficulties. She remained seizure free since the operation in August, 2006 until October, 2006 when the patient decided to taper down her anti-epileptics. It was following this independent dosage change that the patient experienced a recurrence of seizures. However, the seizures have been much less frequent as compared to the past. Currently, she is being maximized on anti-epileptics with the hope that her seizures may be fully controlled. However, if her seizures become refractory to combination anti-epileptics in the future, she may be candidate for surgery again to remove the mesial temporal seizure focus.

